5.04 CHILDBIRTH: COMPLICATIONS: NUCHAL CORD

BLS – FAQ Link

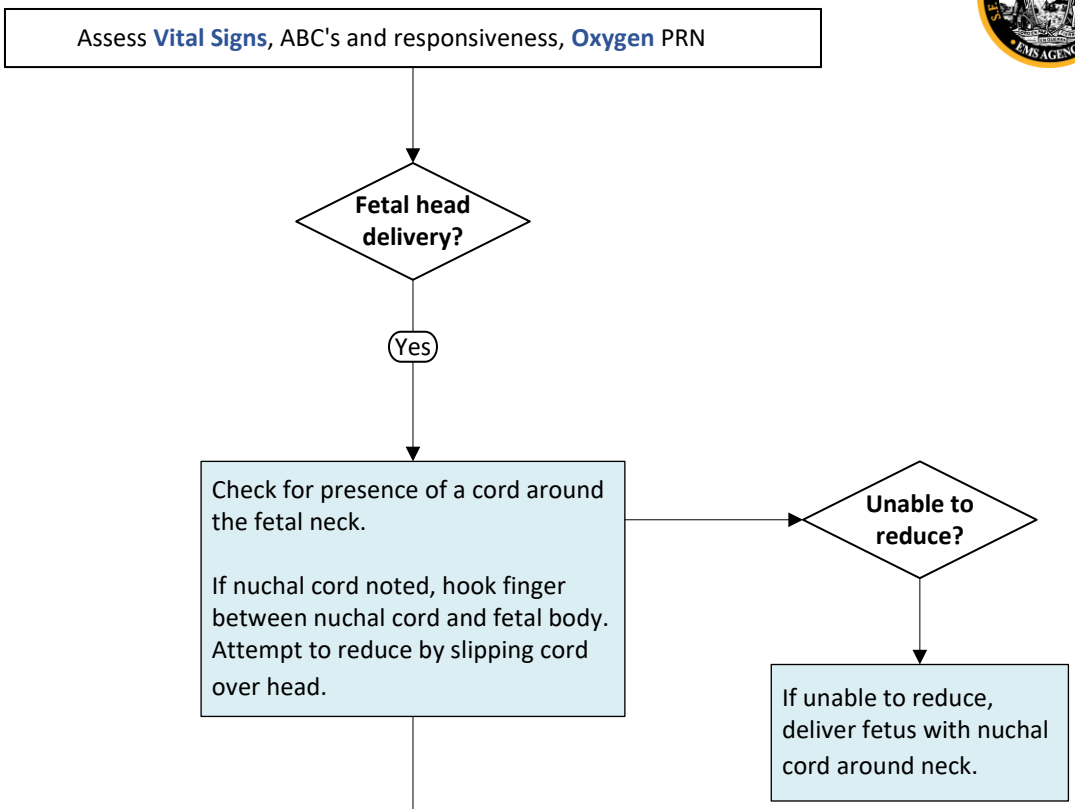

ALS

IV/IO **Normal Saline** TKO

Comments

If multiple nuchal cord loops are noted, reduce one at a time.

Effective: 10/01/24
Supersedes: NEW

5.04 CHILDBIRTH: COMPLICATIONS: SHOULDER DYSTOCIA

BLS – FAQ Link

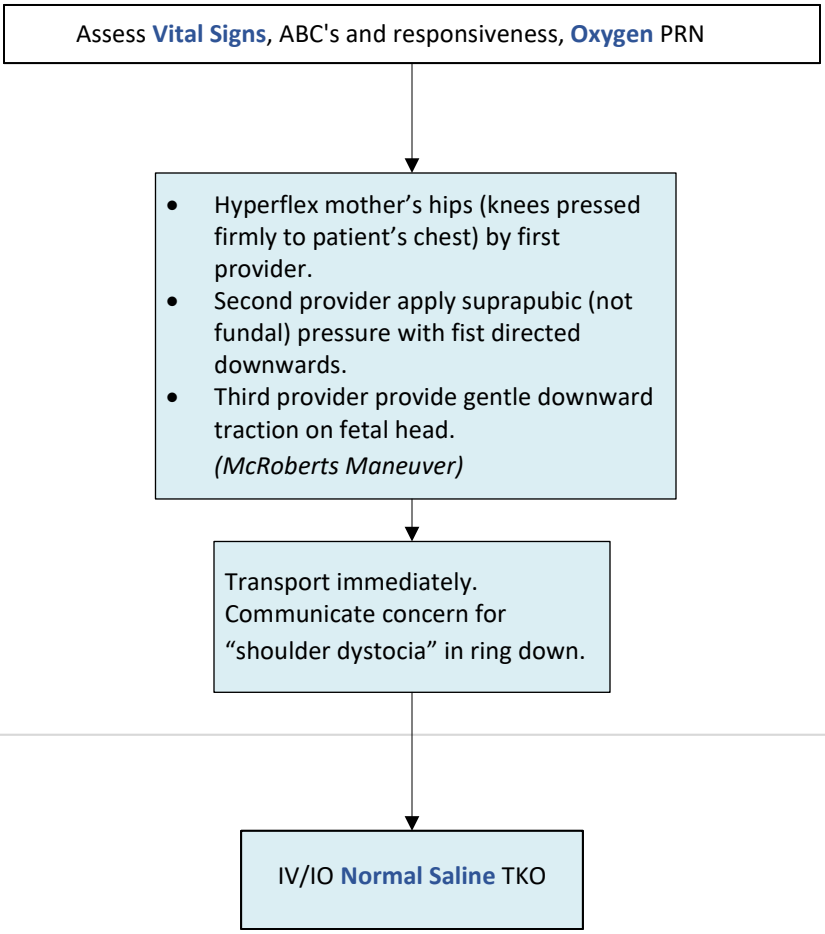

ALS

Comments

- Shoulder dystocia is when the fetal shoulder becomes wedged behind the pubic bone.
- Clinically, fetal head noted to retract back after progressing forward known as the "turtle sign."

5.04 CHILDBIRTH: COMPLICATIONS: BREECH DELIVERY

BLS – FAQ Link

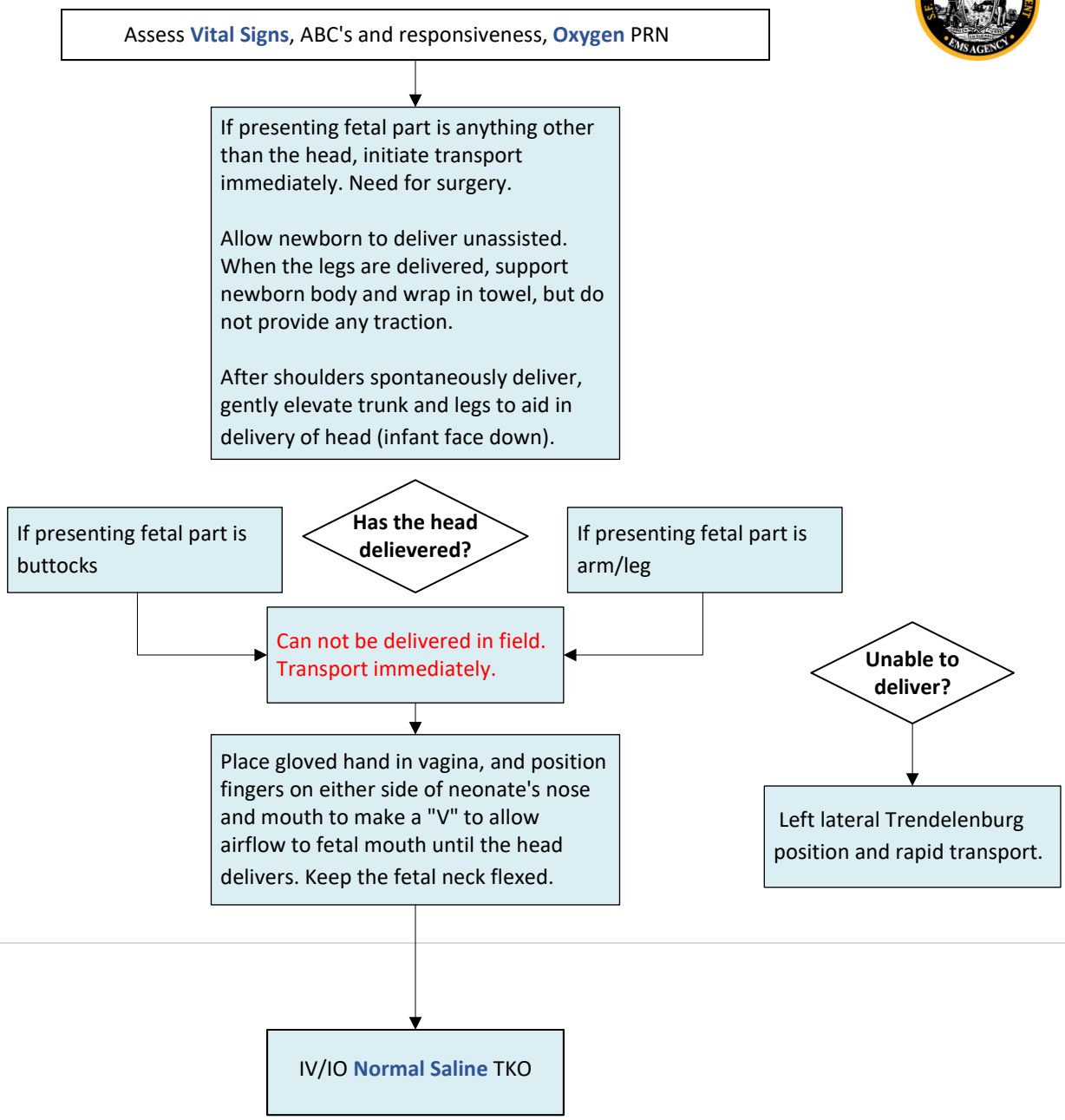

ALS

IV/IO Normal Saline TKO

Comments

- Not all breech presentations can be delivered vaginally, quick transport for potential surgical intervention is critical.
- Allowing spontaneous delivery of fetus up to level of umbilicus increases cervical dilation, decreasing risk of fetal head entrapment.

Effective: 10/01/24
Supersedes: NEW

5.04 CHILDBIRTH: COMPLICATIONS: PROLAPSED CORD

BLS – FAQ Link

Assess **Vital Signs**, ABC's and responsiveness, **Oxygen** PRN

↓

Prolapsed cord visualized?

↓

Left lateral Trendelenburg position and initiate rapid transport as soon as possible.

↓

Cover visible portion of cord with sterile gauze moistened with warm **Normal Saline** (to prevent cord spasm and premature delivery).

Gently displace presenting part of fetus off cord and maintain displacement to achieve pulsatile cord blood flow.

DO NOT pull or over-handle cord in order to prevent cord compression and spasm.

Do NOT reposition or switch providers maintaining displacement.

If provider, such as midwife, has already displaced fetus off cord they should maintain position and transport with patient.

↓

IV/IO **Normal Saline** TKO

ALS

Comments

- Gently displace presenting part of fetus off cord and maintain displacement to achieve pulsatile cord blood flow.
- DO NOT pull or over-handle cord in order to prevent cord compression and spasm.
- Do NOT reposition or switch providers maintaining displacement. If provider, such as midwife, has already displaced fetus off cord they should maintain position and transport with patient.

5.04 Childbirth: Complications

Nuchal Cord

BLS Treatment
• Once fetal head is delivered, check for the presence of a cord around fetal neck. • If nuchal cord noted, hook finger between nuchal cord and fetal body and attempt to reduce by slipping cord over head. • If multiple nuchal cord loops are noted, reduce one at a time. • If unable to reduce, deliver fetus with nuchal cord around neck.

Shoulder Dystocia

BLS Treatment
• Instruct mother to stop pushing immediately. • Perform McRoberts Maneuver: Hyperflex mother's hips (knees pressed firmly to patient's chest) by first provider with second provider applying suprapubic (not fundal) pressure with fist directed downwards with third provider providing gentle downward traction on fetal head. • Transport should be initiated immediately with communication of concern for "shoulder dystocia" in ring down report.
Comments
• Shoulder dystocia is when the fetal shoulder becomes wedged behind the pubic bone. • Clinically, fetal head noted to retract back after progressing forward known as the "turtle sign."

Breech Delivery

BLS Treatment
If presenting fetal part is anything other than head, initiate transport immediately. Need for surgery. Do not delay transport. • Allow newborn to deliver unassisted. When the legs are delivered, support newborn body and wrap in towel, but do not provide any traction. After shoulders spontaneously deliver, gently elevate trunk and legs to aid in delivery of head (infant face down). • If head does not deliver with next contraction, place gloved hand in vagina, and position fingers on either side of the neonate's nose and mouth to make a "V" to allow airflow to fetal mouth until the head delivers. Keep the fetal neck **flexed**.

• If unable to deliver, left lateral Trendelenburg position and rapid transport.
ALS Treatment
• IV / IO with **Normal Saline** at TKO.
Comments
• Not all breech presentations can be delivered vaginally, quick transport for potential surgical intervention is critical. • Allowing spontaneous delivery of fetus up to level of umbilicus increases cervical dilation, decreasing risk of fetal head entrapment.

Prolapsed Cord

BLS Treatment
If prolapsed cord visualized: • Gently displace presenting part of fetus off cord and maintain displacement to achieve pulsatile cord blood flow. DO NOT pull or over-handle cord in order to prevent cord compression and spasm. • Cover visible portion of cord with sterile gauze moistened with warm **Normal Saline** (to prevent cord spasm and premature delivery). • Rapid transport in Left lateral Trendelenburg position. • Do NOT reposition or switch providers maintaining displacement. If provider, such as midwife, has already displaced fetus off cord they should maintain position and transport with patient.
ALS Treatment
• IV/IO with **Normal Saline** TKO.